

# **A Case of a Patient with Left Main Bifurcation with Heavy Calcification**

**Sang Yong Om, MD**

Department of Cardiology, Asan Medical Center,  
University of Ulsan College of Medicine, Seoul, Korea

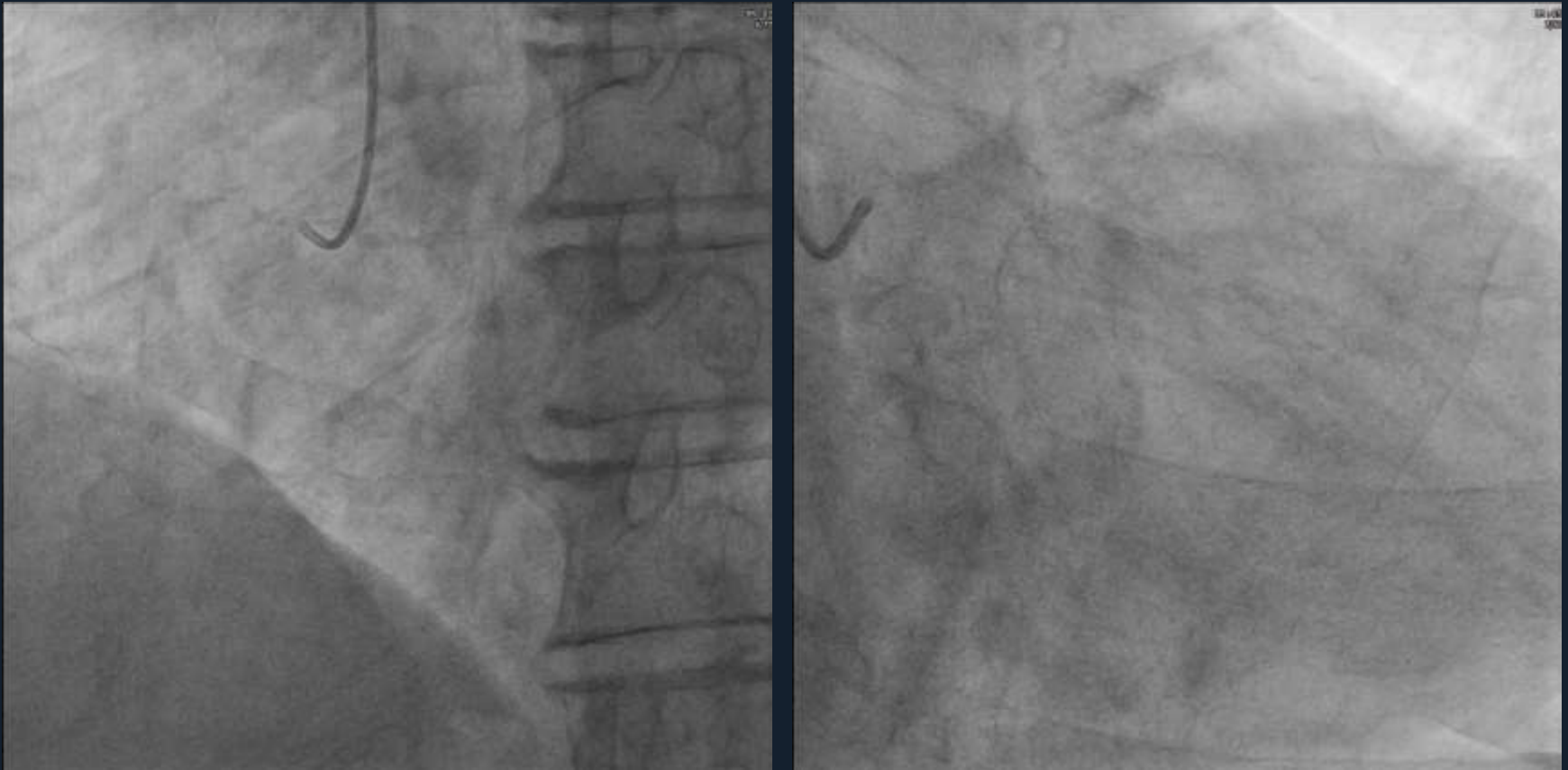
# Brief Case Summary

- **85/M**
- **Chief Complaint:**
  - effort chest pain aggravated from 2 weeks ago
- **Coronary Risk Factors**
  - hypertension, diabetes mellitus
- **Physical Exam : normal**

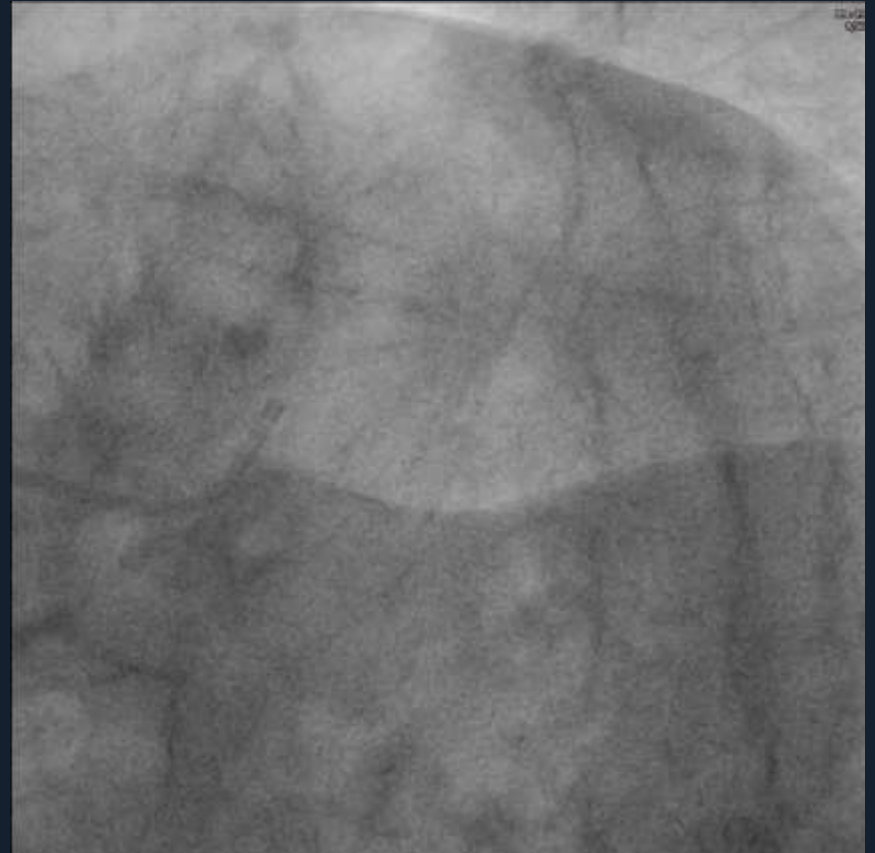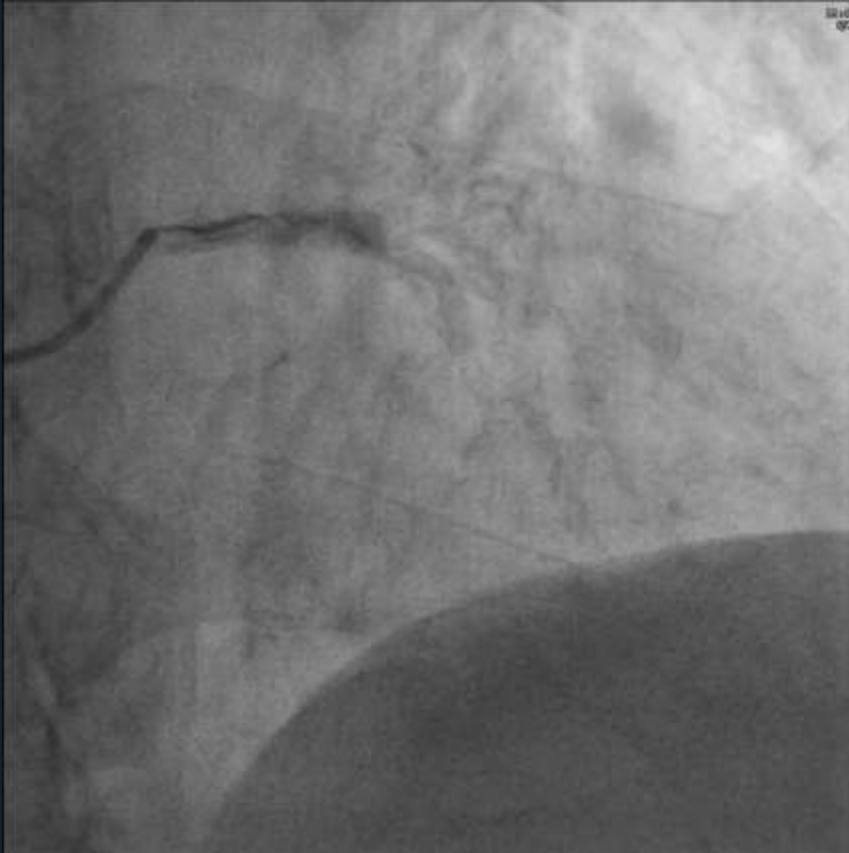
# Brief Case Summary

- **Cardiac Biomarker : normal**
- **ECG : atrial fibrillation**
- **Echocardiography**
  - **Normal LV systolic function without regional wall motion abnormality (LV ejection fraction : 70%)**

# Coronary Angiography



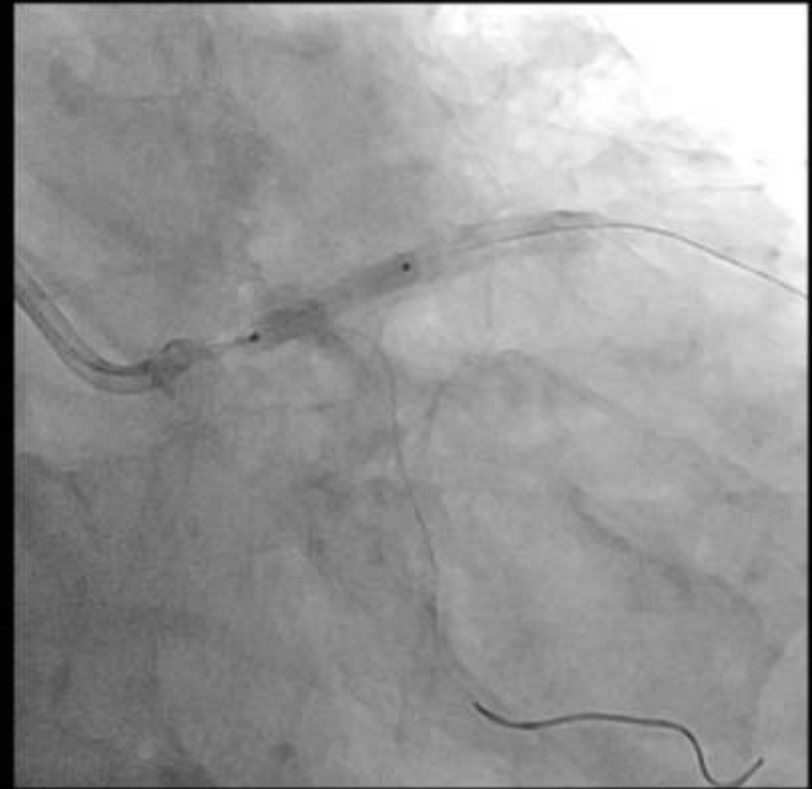
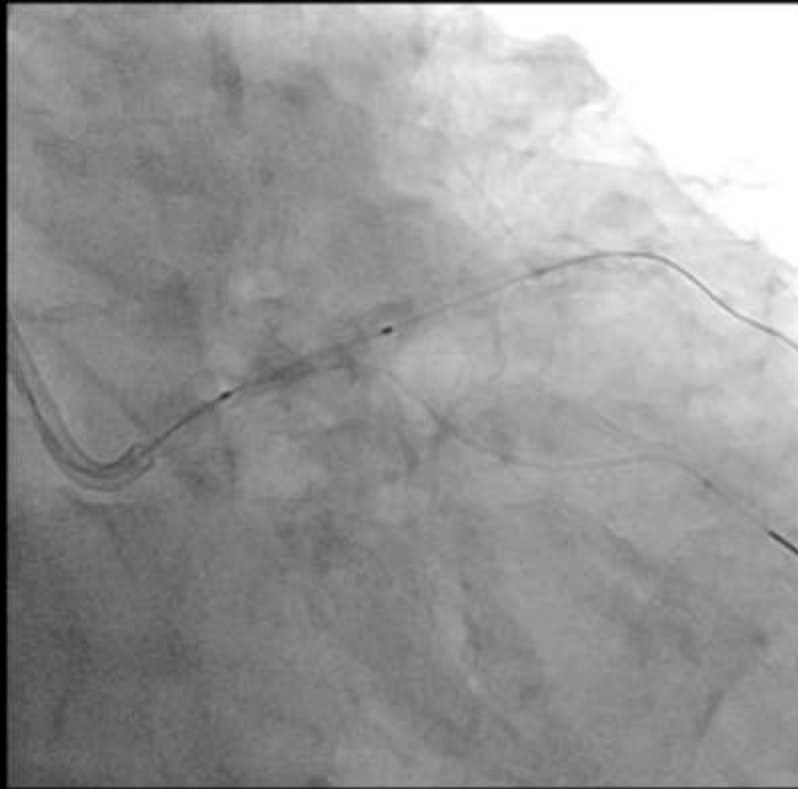
# Coronary Angiography



# PCI Strategy

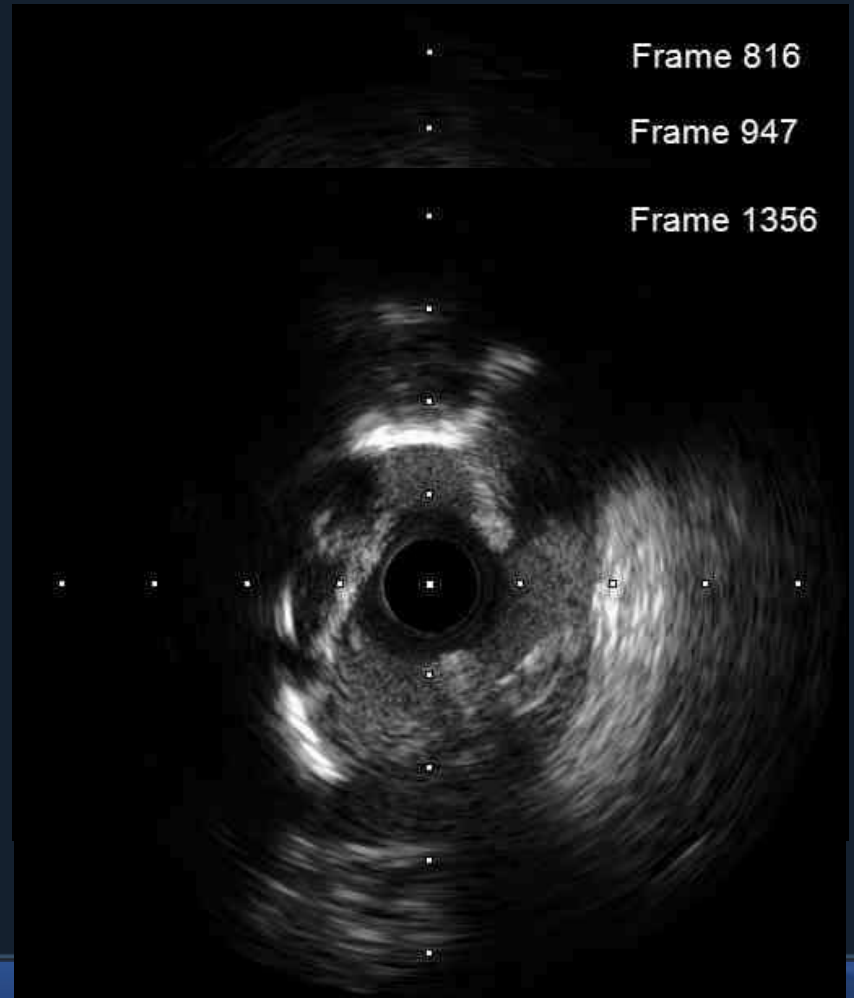
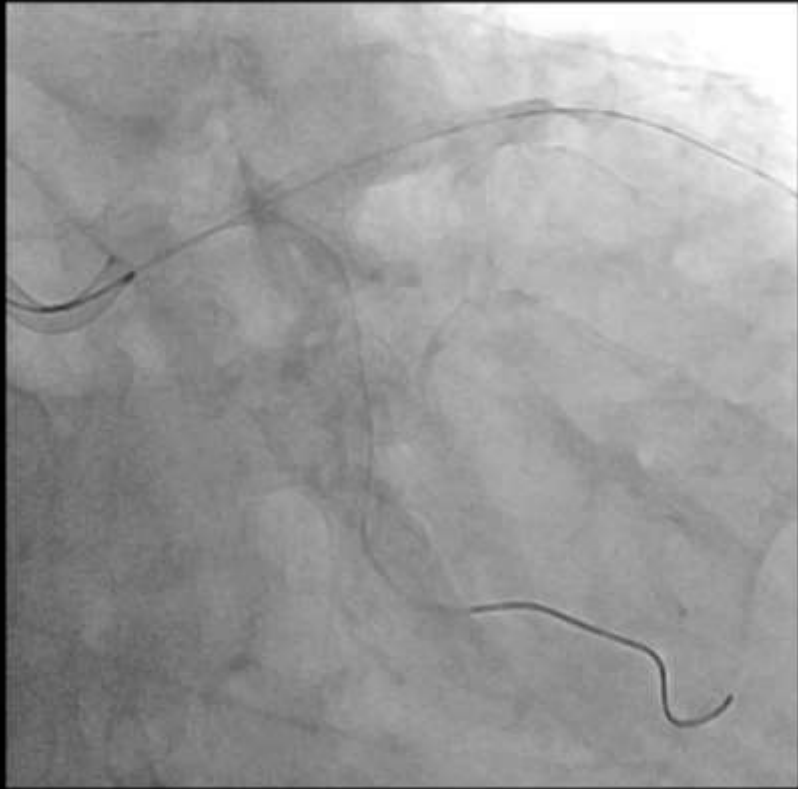- **Target lesion : LM bifurcation & pmLAD & pLCX**
- **Crush technique**
- **Planned devices**
  - **drug-eluting stent**
  - **noncompliant balloon**
  - **scoring balloon**
  - **prn) rotablation**

# Wiring and Predilation



2.5(18) NC balloon → 3.0(15) scoring balloon → 3.75(18) NC balloon

# Post-balloonning & IVUS (LAD)



Frame 816

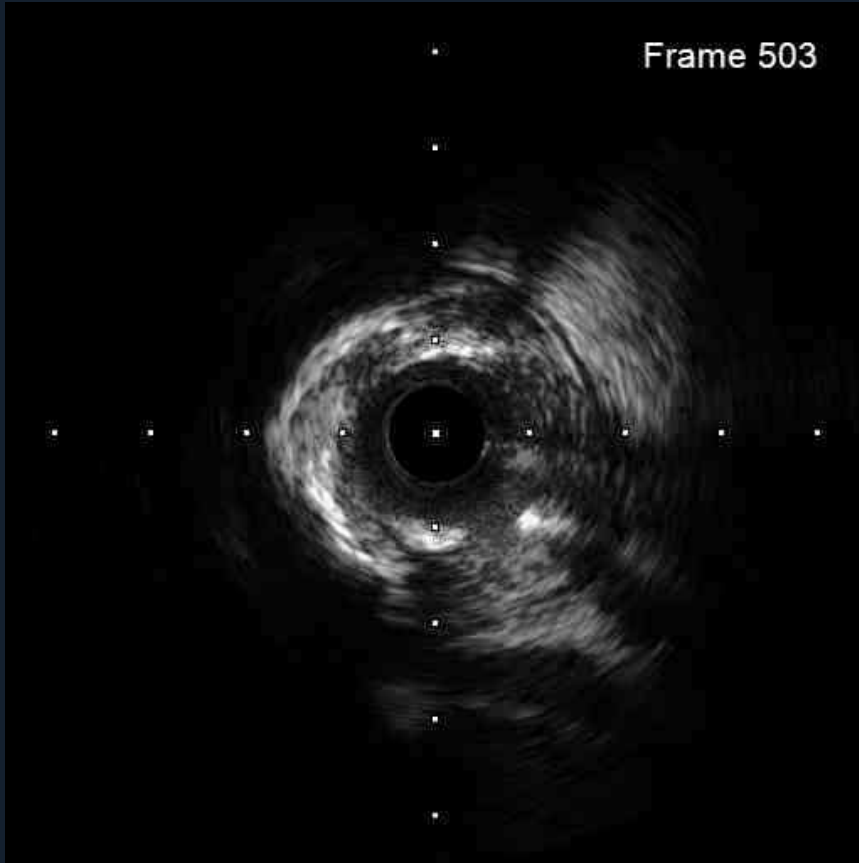Frame 947

Frame 1356

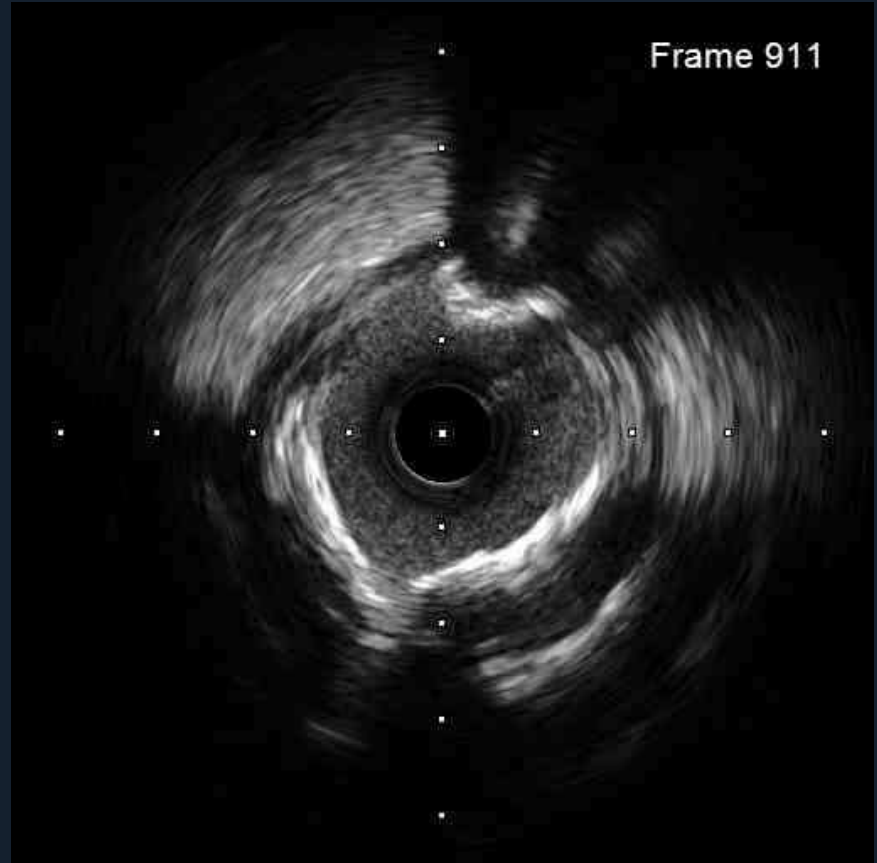


# Post-ballooning & IVUS (LCX)

Frame 503

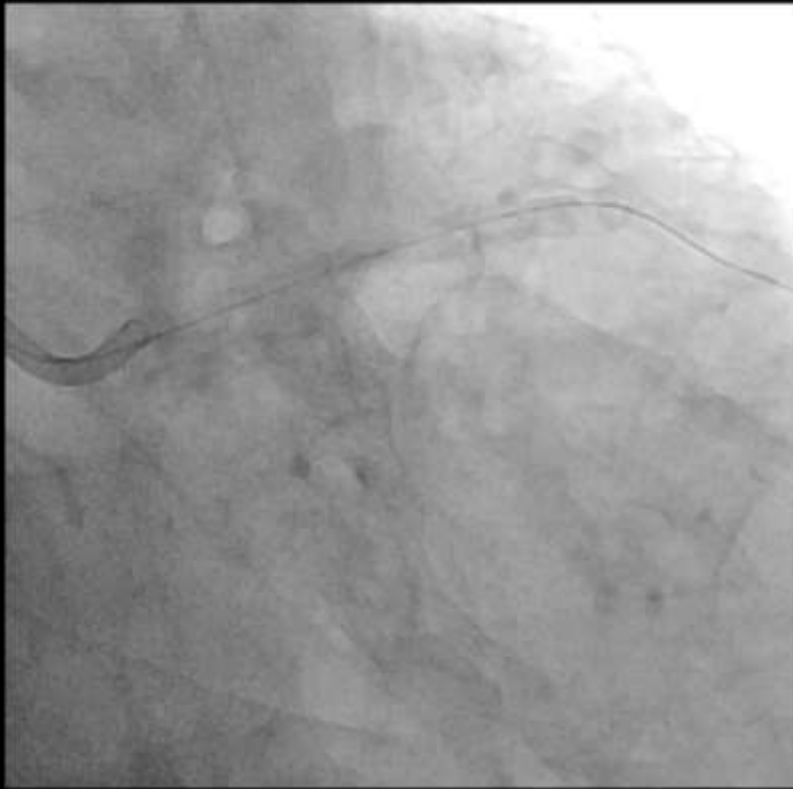

Frame 911



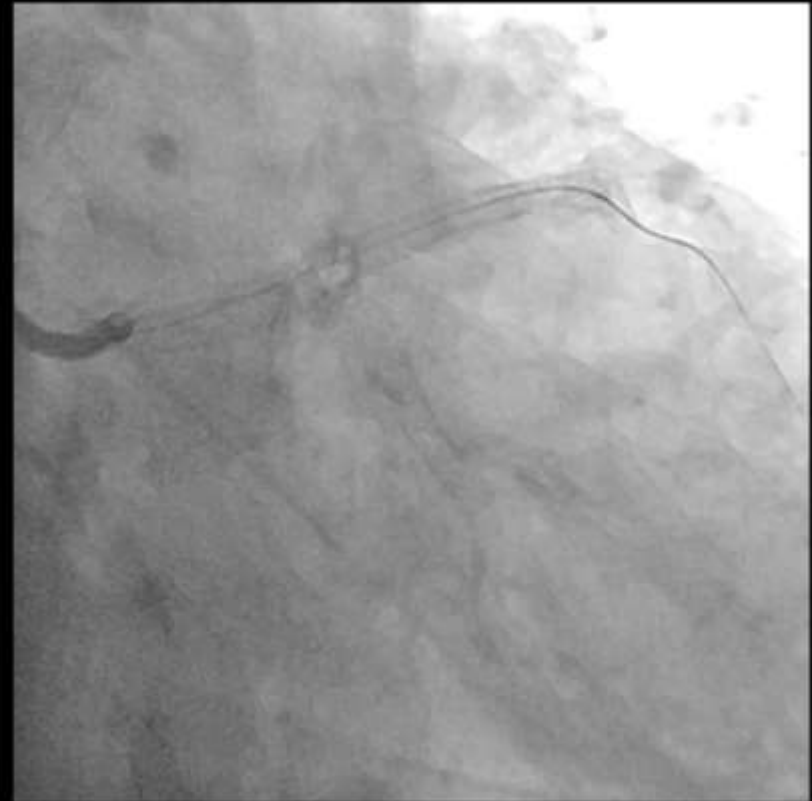
# Crush

LCX



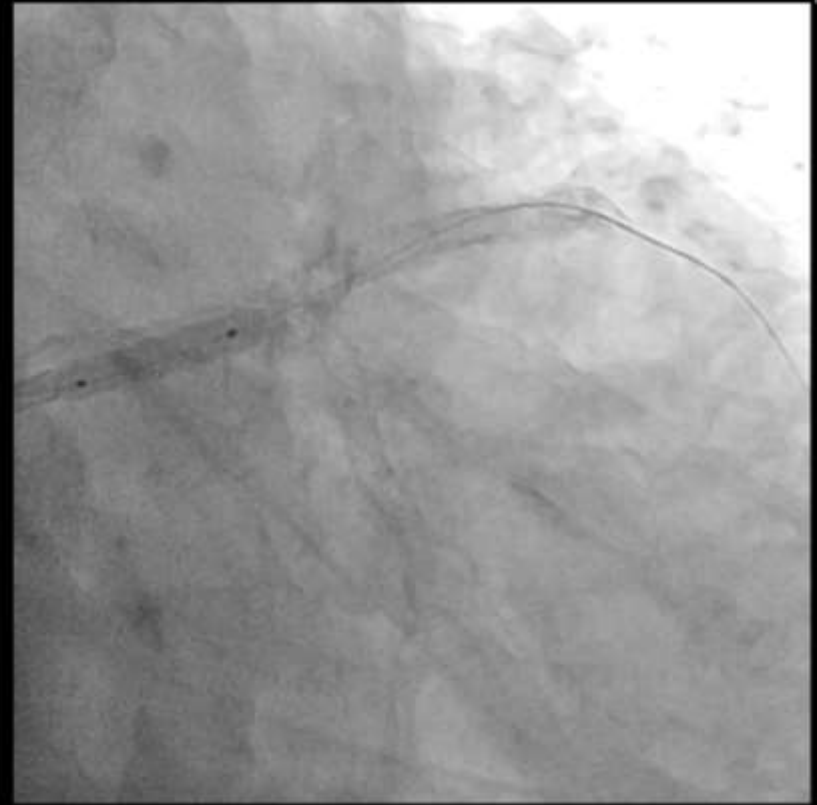
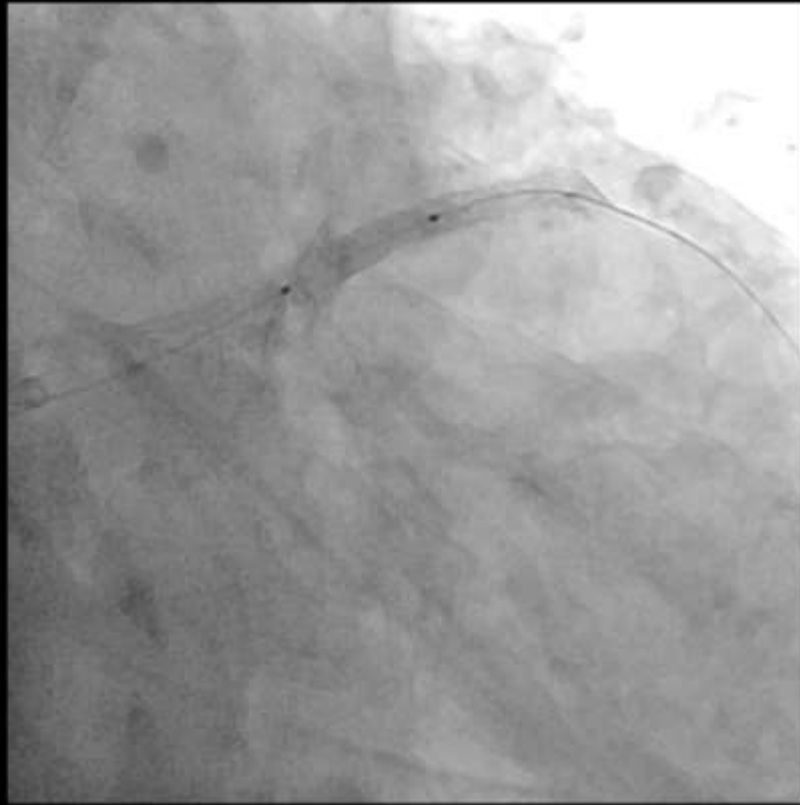
**Xience Alpine 3.5(28)**

LAD



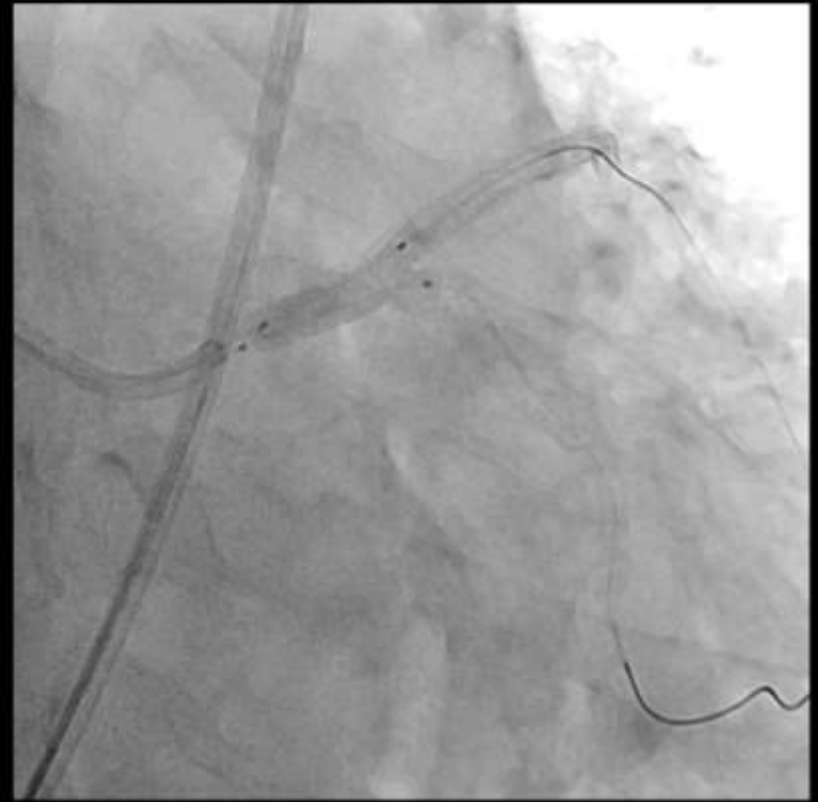
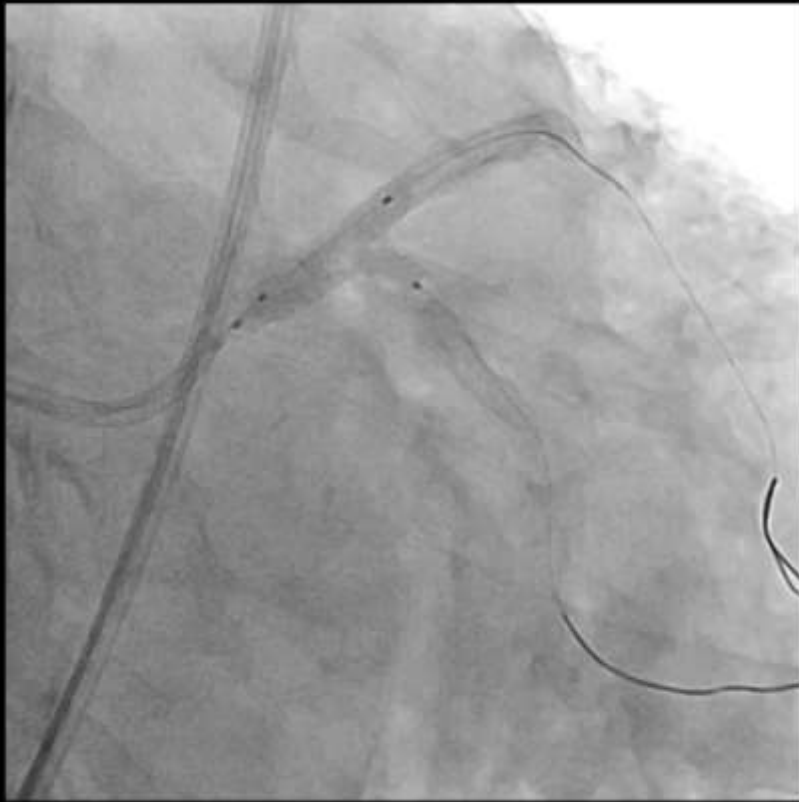
**Xience Alpine 3.0(28)+3.5(38)**

# Postdilatation



**3.0(20) / 3.75(18) / 4.0(15) NC balloon**

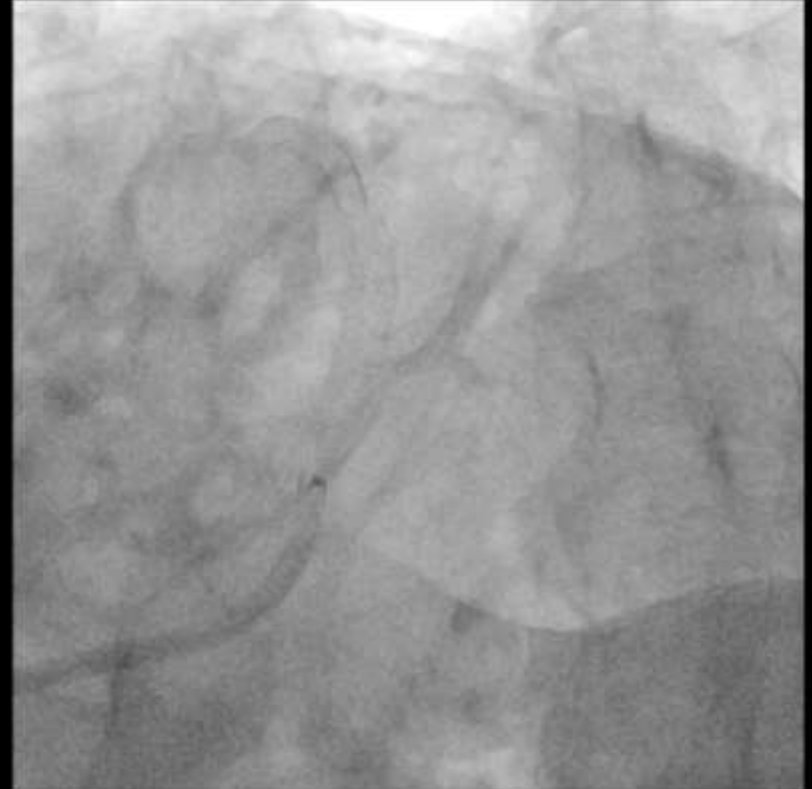
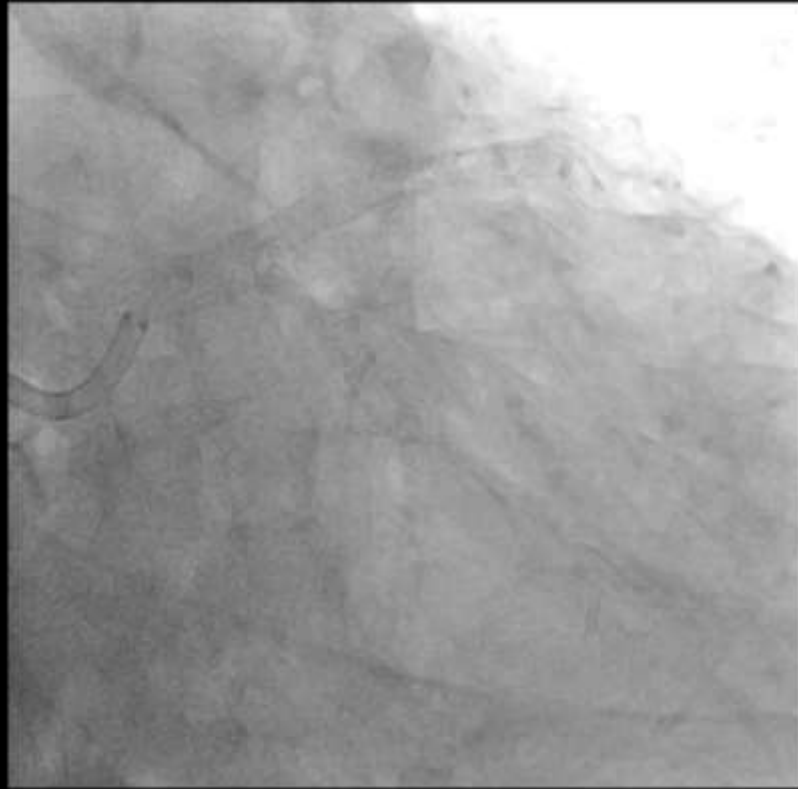
# Kissing Ballooning



**pLCX : 3.0(20) NC balloon upto 10atm(2.9)**

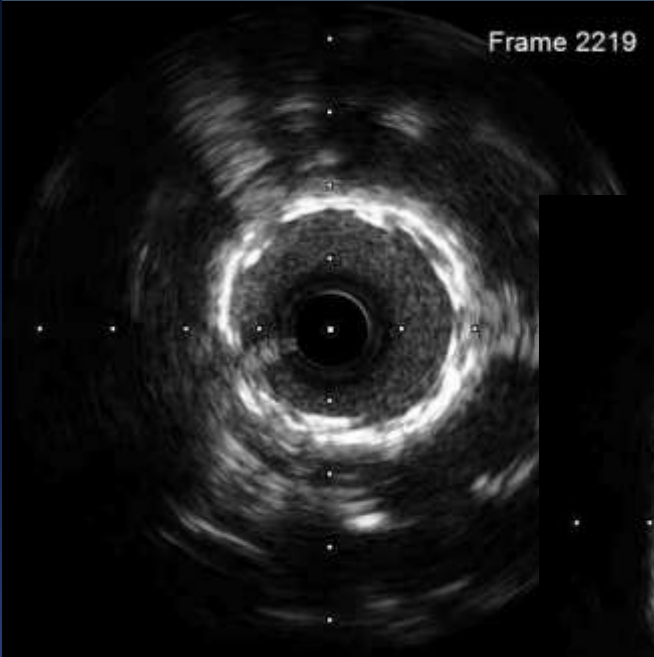**LM-pLAD : 3.75(18) NC balloon upto 10atm(3.7)**

# Final Angiogram

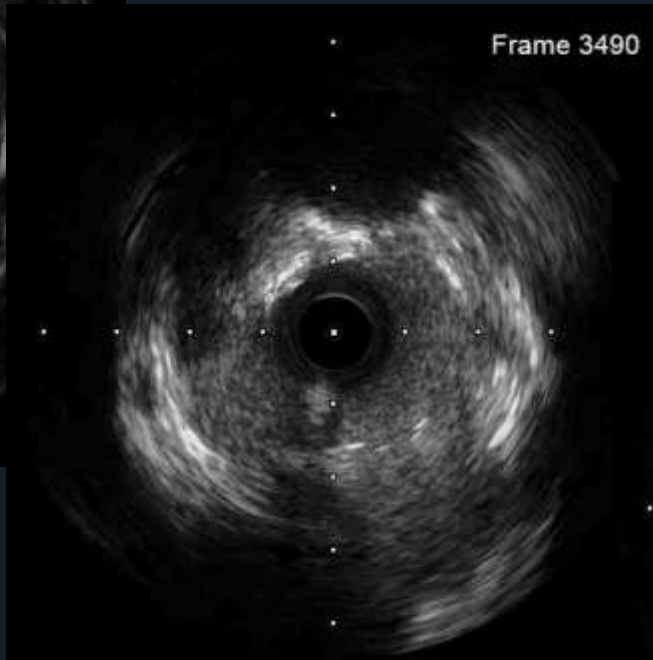


# Final IVUS (LM-LAD)

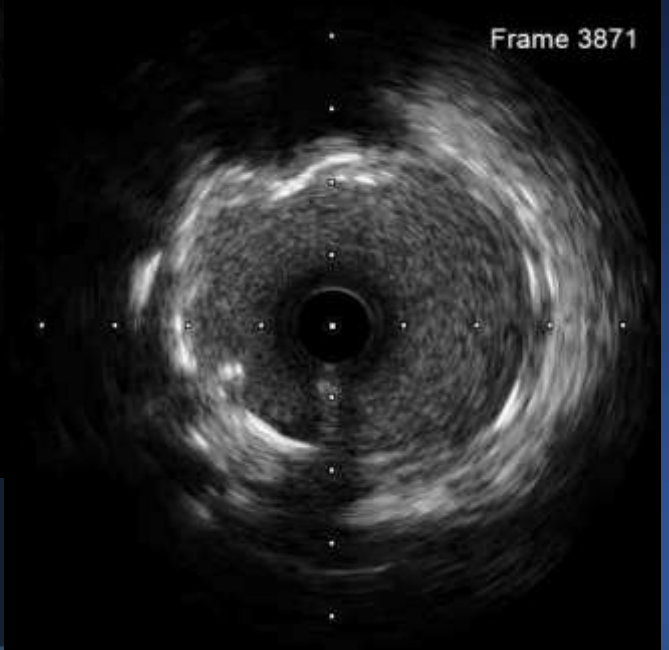
Frame 2219



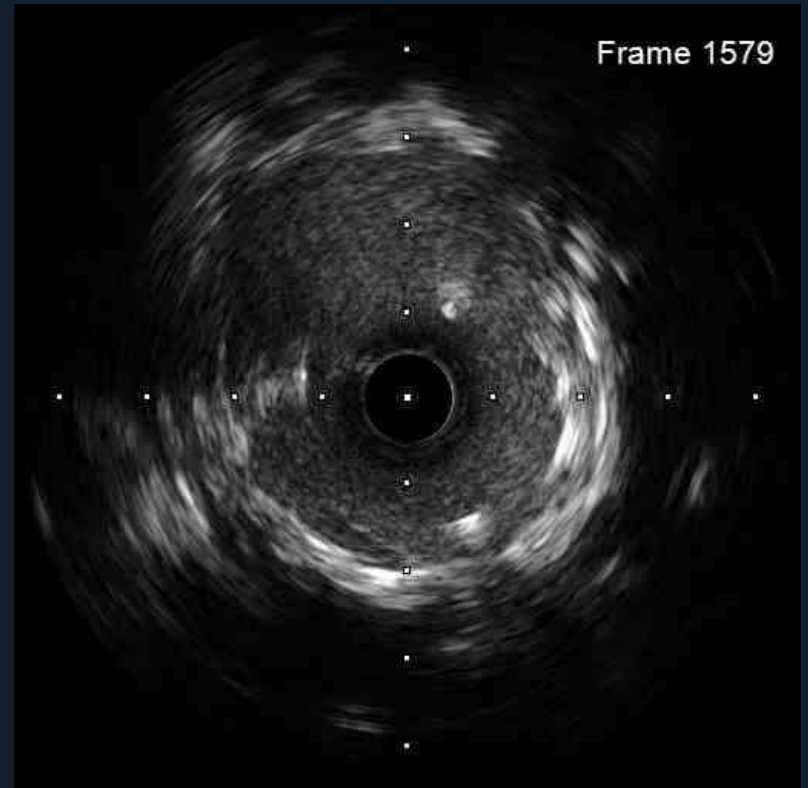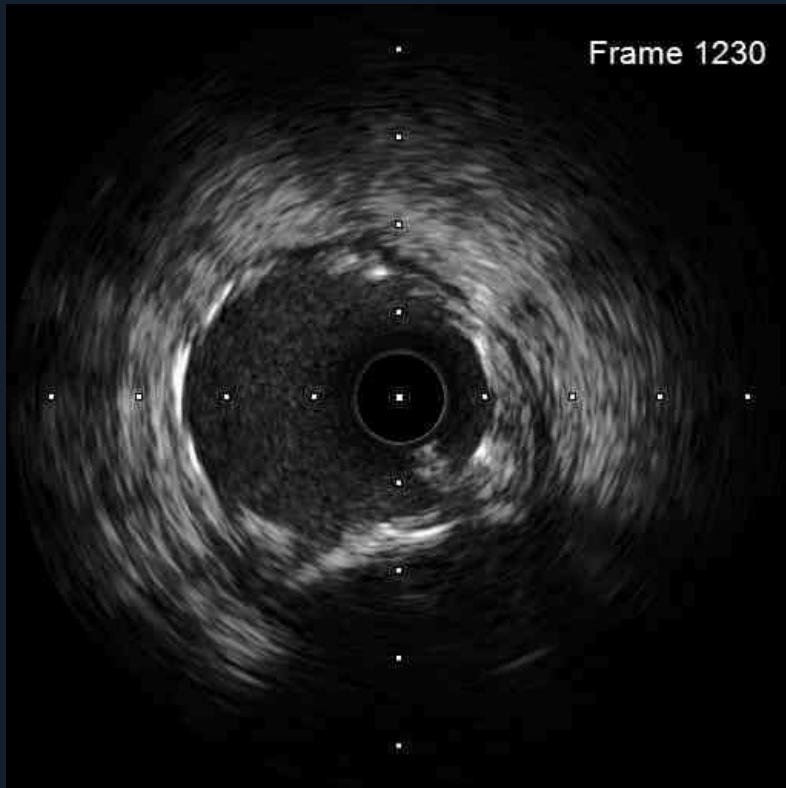
Frame 3490



Frame 3871



# Final IVUS (LCX)



**Thank you for your attention !**